

Application of robotic assisted technology and imaging devices in autopsy and virtual autopsy

Ladan Soltanzadeh¹, Mehrdad Imanzadeh² and Hamid Keshvari^{*3}

¹ is with Educational Deputy of Urmia University of Medical Sciences, Msc
In Biomedical Eng, Amirkabir University of Technology, Iran

² is with Biomedical Engineering Faculty, Amirkabir University of
Technology, Tehran, Iran

^{*3} (Corresponding Author) is with Assistant professor of Department of Biomedical Engineering, Amirkabir
University of Technology, 424 Hafez Ave, Tehran, Iran, 15875-4413, Tel: (+98) 21 64 54 24 81

Abstract

Introduction: Virtual autopsy is one of the applied technologies in telemedicine serverices. This study aimed to review application of technological capabilities of virtual autopsy in telemedicine forensic services.

Methodology: A review using the keywords related to "*Virtual autopsy*", "*Autopsy*", "*Telemedicine*", "*Robotic assisted technology*", "*Imaging Device*", "*forensic*" to search for articles in the databases Pubmed, Proquest, ScienceDirect Google Scholar, Elsevier, SID and Magiran carried out from 2006 to 2014. Related article 42 of the 175 articles was excluded.

Findings: Virtual Autopsy was first used in 2006 in the Swiss capital. This average takes about 30 minutes and the results of forensic investigators placed.

Conclusion: virtual autopsy can be used as a complement to conventional autopsy. This process also improves the quality of forensic pathology research. The various processing techniques can be strong forensic evidence for use in legal proceedings to offer.

Keywords: *Virtual autopsy, Autopsy, Telemedicine, Robotic assisted technology, Imaging Device, forensic*

1. Introduction

Forensic pathology is one of the most original and the most important sections of the judicial and criminal science that its main objective in most countries is to determine the cause of death of the man who lost their lives for various reasons. Forensic pathologists are provided with a collection of tools, equipment and techniques to determine the cause of death and autopsy is one of the most common techniques.

Autopsy is defined as cutting out and separating the parts of the body for study [1].

An autopsy is done for the educational purposes of judging and diagnostic purposes.

Educational autopsy, which is often used in anatomy halls of universities is considered as an essential tool for teaching students and pathology residents. The judicial autopsy is performed by forensic pathologists after judicial authority order following guardians' sue to ascertain whether the deceased died as a result of illness or accident, or is murdered. The results of this type of autopsy are court friendly.

Diagnostics autopsy can be made by pathologists with the aim of discovering the disease caused the death of the deceased [2].

The use of the traditional autopsy that is done aggressively is declining [3]. There exists a lack of willingness to do autopsy among pathologists well as people. Different communities are reluctant to do a traditional autopsy because of the emotional, cultural and religious factors.

Being time consuming, inconvenient and contradictory and incomplete reports, high cost, the risk of transmission of blood pathogens such as HIV+ and hepatitis C are also causes of lack of desire of pathologists to do autopsy [4] [5] [6].

Michael Thali et al, the Professor of the University of Berne, introduced system under the name of Virtopsy or virtual autopsy helping to specifying the cause of death without splitting a corpse. This method has been utilized since 2006 to discover the cause of the sudden deaths in the capital of Swiss [2].

Virtual autopsy is an available technology that could be used in telemedicine. This service is a non-invasive method in forensic services, identifying 60 to 80 percent of the causes of injuries or without any damage to the human body tissues. In recent years, this procedure is used as a complement to the conventional autopsy and includes a variety of modern medical imaging techniques with some special applications in forensic [7] [8] [9].

Virtual autopsy can provide vital information about the body that obtaining them is difficult and time consuming using conventional tools. In this method the images of brain injuries, bone fractures and even images of soft tissues of the body and the blood vessels can be provided [10][11].

Virtual autopsy essential devices include:

- A variety CT scan devices such as Micro CT, Multi-Slice Computed Tomography(MSCT), Magnetic Resonance Imaging(MRI), Microscopic MRI, Magnetic Resonance Spectroscopy, 3-D CAD/Photogrammetry.
- Other devices such as three-dimensional optical scanner of the body, Biopsy Module, Angiography unit, a navigation system unit (arm) that can be used for direct imaging and a computer system for documenting, equipped with 3D simulation software [12] [13].

Multi CT scan and MRI could be utilized in the diagnosis of severe fractures, bullet path, rotting, cardiovascular damages, drowning, blood clots, foreign body, brain and lung damage, documenting damage, planning autopsy, limited autopsy.

The resulting digital images have considerable applications in the medical field for the diagnosis, education and research. Several post processing techniques could present strong forensic evidence for use in legal proceedings [14].

Studies show that virtual autopsy could be regarded as a supplement to autopsy [15].

The goal of this study was the technological evolution of the use of virtual autopsy capabilities in the format of telemedicine services.

2. Methodology

This study is a review using the keywords related to "Virtual autopsy", "Autopsy", "Telemedicine", " Robotic assisted technology", "Imaging Device", " forensic " to search for articles in the databases Pubmed, Proquest, ScienceDirect Google Scholar, Elsevier, SID and Magiran carried out from 2006 to 2014. Related article 42 of the 175 articles was excluded.

3. Findings

Progress in the field of telecommunication and digital technology and the computer has had a great impact on medical imaging. Today, manipulating images is possible through digital imaging systems so that important and desired parts of the image could be selected algorithmic processes to obtain necessary diagnostic data [16] [17]. Therefore, one can improve the accuracy and quality of the images with the various Imaging methods leading to the detection quality enhancement and ultimately reducing the cost of testing. At the present time Imaging technology and saving, observation, and sanding have been improved significantly [18] [19].

Picture Archiving & Communication Service (PACS) are responsible for archiving, transferring, restoring, displaying and processing images in the digital networks. This system includes a collection of web based software receiving pictures from imaging systems with digital output such as MRI, CT scan and Digital radiography.[20] [21]

Digital Imaging and Communication in Medicine (DICOM) is a standard in the field of system communication and all the imaging systems should be compatible with this standard [22].

Picture Archiving and Communication Systems (PACS) facilitates storing, processing, viewing images and its related information for the doctors using Health Level Seven International (HL7) and DICOM alongside

information systems for the management of the images [24] [25] [26].

The components of a system of communication and image recovery include imaging device, a computer for getting pictures from imaging devices, control section of communication systems and image recovery, including the server, database, and the archive [27] [28] [29] [30].

Picture Archiving and Communication Systems are able to send and receive digital medical pictures in DICOM format to DICOM Work Stations of local area network work station [31] [32] as well as connect to Web PACS network for remote Internet communication and the archive and retrieve the information in database [33].

A robot under the name of virtobot has been invented in Institute of legal medicine at the University of Bern doing virtual autopsy. This robot scans around the dead tissue with light radiation and takes photos with high quality. Some pictures are provided by CT scan at the same room. Then this information combined together to produce three-dimensional images that can be kept for a long time and be used in forensic tests. Additionally robot is also able to do CT guided biopsy. In fact, Virtobot is a research unit that reunites all autopsy technologies [31] [33].

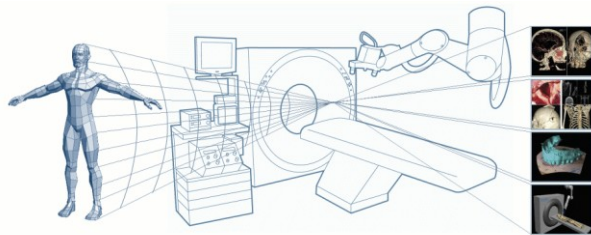


Fig 1. General scheme of virtual autopsy or virtopsy

In the virtual autopsy the corpse is placed on the surface and imaging is done using Radiology imaging tools such as CT scan, MRI and angiography, then filtering is performed with the use of software systems based on density, texture, transparency, and other criteria, the necessary information is stored in a computer system, then this information is assessed by a special software, and then reconstruction of autopsy images is done and results are presented to Forensic pathologists. Virtual autopsy takes about 30 minutes [34].

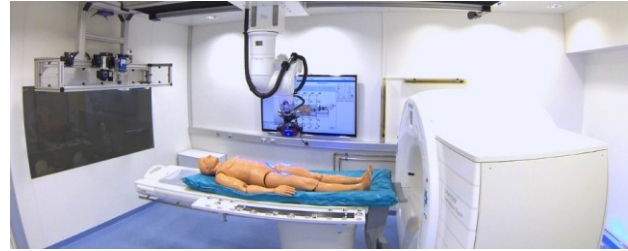


Fig 2. Research unit of virtual autopsy

Swedish researchers designed interactive touchscreen 3D autopsy table that allows pathologists to virtually check the actual body in details from multiple angles. Using the information provided by the scan of an actual body interactive touchscreen 3D autopsy table give this possibility to users to remove layers including the skin and the muscle or blood circulation system and zoom inside the body through cutting with a virtual knife.



Fig 3. interactive touchscreen 3D autopsy table

Interactive touch screen 3D autopsy table which is designed at the Norrköping Visualization Center in collaboration with Medical Image Science and Visualization is now used in criminal investigations and caused the autopsy process improvement.

4. Conclusions

From the disadvantages of a Virtopsy can be pointed out to the inability of an MRI imaging device system for imaging of the coronary artery lesions, differentiation of blood clots in the veins after the death, of pulmonary thrombosis differentiation of breast second-hand.

The significant cost, yet turn for access to imaging devices and some of the inherent limitations of technology, standardization of the process of Virtopsy, the initial cost of establishing these systems are problems hindering extensive use of Virtopsy in developing countries [35].

The non-invasive nature of Virtopsy in cases where religious or ethical concerns arise makes it more

acceptable [33]. Also the body remains intact in Virtopsy and therefore the victim's family does not feel grief. This overcomes obstacles of autopsy inhibition introduced by religions [34] [35].

At autopsy it is difficult to distinguish the location and number of foreign bodies, tiny fractures of bone and volume of gas or fluid while in Virtopsy internal bleeding, the bullet path and hidden fractures that are difficult to be found in a traditional autopsy are detected. Also, it is possible to detect bone fracture patterns, fragmentation, brain soreness, bullet path, emboli and aspiration of blood to the lung with the help of DC scans and MRI [36].

Detailed documentation of findings on physical examination of the bodies is achieved in Virtopsy so that it is feasible to do virtual autopsy in any time and in any place including the court and long after destruction of the corpse [37]. Three dimensional images of Virtopsy are shown easily in the courts rather than the terrible images of the traditional autopsy of the victim's body.

The data provided for forensic and pathologists by Radiology techniques and modern imaging technologies in Virtopsy have more accurately than the human eye if carefully is interpreted. Transportation of Real examples is difficult for pathologists, while the digital image of the body can be shared electronically among forensic pathologists and doctors and be saved for future study, as well as the exchange and dissemination of information through the Internet is possible. Forensic pathologists are able to do autopsy through the Internet, so some hospitals no longer need to employ forensic pathologists [38]. In other words, forensic pathology is achieved by creating permanent digital files of the body for forensic pathologists and remotely communicating with each other and medical consultations [39].

Although the device is required in performing a virtual autopsy are very expensive, but the process of Virtopsy in the use of resources is much cheaper than conventional autopsy and it would be a lot easier. [40][41][42].

Uses of the virtual autopsy capabilities provide enhanced services in forensic medicine and increase the accuracy of autopsy process. Virtopsy makes evidences clear and tangible and make improvements to identify the causes of the incident and assess the findings and the results. In Virtopsy connection can be established with a mouse click and the need for tools of traditional autopsy is no longer required. In fact the idea of a virtual knife is coming into reality. Virtopsy is an "all-in-one" solution and a model

that have benefited from that [43]. By considering these capabilities, we can present many forensic services in the form of an effective telemedicine system.

Acknowledgments

This project is part of Biomedical Engineering MS student's Project in Telemedicine Course with tendency Medical information technology management of Amirkabir University of Technology, Tehran, Iran (Corresponding Author) Assistant professor of Department of Biomedical Eng., Amirkabir University of Technology, Department of Biomedical Eng. Amirkabir University of Technology
424 Hafez Ave, Tehran, Iran, 15875-4413, Tel: (+98) 21 64 54 24 81
Email: Keshvari@aut.ac.ir

References

1. Bolliger S A, Thali MJ, Ross S, Buck U, Naether S, Vock P. Virtual autopsy using imaging: bridging radiologic and forensic sciences: a review of the Virtopsy and similar projects. *Eur Radiol* 2008;18(2): 273-82.
2. Thali M J, Jackowski C, Oesterhelweg L, Ross S G, Dimhofer R. VIRTOPSY—the Swiss virtual autopsy approach. *Leg Med* 2007;9(2): 100-4.
3. Flach PM, Ross SG, Bolliger SA, Preiss US, Thali MJ, Spendlove D. Postmortem whole-body computed tomography angiography visualizing vascular rupture in a case of fatal car crash. *Arch Pathol Lab Med* 2010; 134(1): 115-19.
4. Rütty G N. Are autopsies necessary?. *Rechtsmedizin* 2007; 17(1): 21-8.
5. Horowitz RE, Naritoku WY. The autopsy as a performance measure and teaching tool. *Human Pathol* 2007; 38(5): 688-95.
6. Krukemeyer MG, Dankof A, Krenn V, Hansen D, Dietel M. Necessity of increasing autopsy frequency following the introduction of DRGs. *Der Pathologe* 2007;28(4): 294.
7. Harrington DE, Edward AS. Managed care and measuring medical outcomes: Did the rise of HMOs contribute to the fall in the autopsy rate?. *Soc Sci Med* 2010; 70(2): 191-8.
8. Westphal SE, Apitzsch J, Penzkofer T, Mahnken AH, Knüchel R. Virtual CT autopsy in clinical pathology: feasibility in clinical autopsies. *Virchows Arch* 2012; 461(2): 211-19.

9. Sebire NJ. Towards the minimally invasive autopsy?. *Ultrasound Obstet Gynecol* 2006; 28(7):865-7.
10. Oluwasola OA, Fawole OI, Otegbayo AJ, Ogun GO, Adebamowo CA, Bamigboye AE. The autopsy: knowledge, attitude, perceptions of doctors and relatives of the deceased. *Arch Pathol Lab Med* 2009; 133(1): 78-82.
11. Dirnhofer R, Jackowski C, Vock P, Potter K, Thali M J. Virtopsy: minimally invasive, imagingguided virtual autopsy. *Radiographics* 2006;26(5): 1305-33.
12. Said F, El Beshlawy A, Hamdy M, El Raziky M, Sherif M, Ragab L. Intrafamilial transmission of hepatitis c infection in egyptian multitransfused thalassemia patients. *Trop Paediatr J* 2013.
13. Burton, Julian L, Underwood J. Clinical,educational, epidemiological value of autopsy.*Lancet* 2007; 369(9571): 1471-80.
14. Sosa-Iudicissa M, Wooton R, Ferrer-Roca O.Historia de la Telemedicina. In: *Telemedicina*.Madrid: Panamericana; 2001. P.1-18.
15. Soltanzadeh L, Imanzadeh M, Keshvari H. VIRTUAL AUTOPSY IS SUPPLEMENT FOR AUTOPSY. *URMIA MEDICAL JOURNAL*. 2013; 24 (4) :263-276.[Persian]
16. Ebert LC, Ptacek W, Naether S, Fürst M, Ross S,Buck U, Thali, M. Virtobot-a multi-functional robotic system for 3D surface scanning and automatic post mortem biopsy. *Int J Med Robot Comp* 2010;6(1): 18-27
17. Wichmann D, Obbelode F, Vogel H, Hoepker WW, Nierhaus A, Braune S, et al. Virtual Autopsy as an Alternative to Traditional Medical Autopsy in the Intensive Care UnitA Prospective Cohort Study. *Annals of internal medicine*. 2012;156(2):123-30.
32. Faggioni L, Neri E, Castellana C, Caramella D,Bartolozzi C. The future of PACS in healthcare enterprises. *Eur J Radiol* 2011; 78(2): 253-8.
18. Aghayev E, Staub L, Dirnhofer R, Ambrose T, Jackowski C, Yen K, et al. Virtopsy—the concept of a centralized database in forensic medicine for analysis and comparison of radiological and autopsy data. *J Forensic Sci Leg Med* 2008; 15(3):135-40.
19. Nissan E. Virtopsy: the virtual autopsy in computer applications for handling legal evidence,police investigation and case argumentation.Netherlands: Springer; 2012. P. 991-1015.
20. Levy AD, Harcke HT, Getz JM, Mallak CT, Caruso JL, Pearse L, et al. Virtual Autopsy: Two-and Three-dimensional Multidetector CT Findings in Drowning with Autopsy Comparison 1. *Radiology*. 2007;243(3):862-8.
21. van de Wetering R, Batenburg R. A PACS maturity model: a systematic meta-analytic review on maturation and evolvability of PACS in the hospital enterprise. *Int J Med Sci Info* 2009;78(2):127-40.
22. Amis ES, Butler PF, Applegate KE, Birnbaum SB, Brateman LF, Hevezi JM, et al. White Paper on Radiation Dose in Medicine. *J Am Coll Radiol*2007;4:272-84.
23. Mackinnon AD, Billington RA, Adam EJ, Dundas DD, Patel U. Picture archiving and communication systems lead to sustained improvements in reporting times and productivity:results of a 5-year audit. *Clin Radiol* 2008;63(7):796-804.
24. Reijns GL. Integration in PACS of DICOM with TCP/IP, SQL, X Windows in medical imaging. *Int Soc Opt Photo* 1994: 744-53.
25. Ikeda G, Yamamoto R, Suzuki M, Ishikawa H,Kikuchi K, Shiotani S. Postmortem computed tomography and magnetic resonance imaging in a case of terminal-stage small cell lung cancer: an experience of autopsy imaging in tumor-related death. *Radiat Med* 2007;25(2) : 84-7.
26. Yokota H, Yamamoto S, Horikoshi T, Shimofusa R, Ito H. What is the origin of intravascular gas on postmortem computed tomography?. *Leg Med* 2009;11 : 252-5.
27. Shiotani S, Ueno Y, Atake S, Kohno M, Suzuki M, Kikuchi K, et al. Hayakawa Nontraumatic postmortem computed tomographic demonstration of cerebral gas embolism following cardiopulmonary resuscitation. *JPN J Radiol* 2010;28 : 1-7.
28. Germerott T, Flach PM, Preiss US, Ross SG,Thali MJ. Postmortem ventilation: a new method for improved detection of pulmonary pathologies in forensic imaging. *Leg Med* 2012; 14: 223-8.
29. Michiue T, Sakurai T, Ishikawa T, Oritania S,Maeda H. Quantitative analysis of pulmonary pathophysiology using

postmortem computed tomography with regard to the cause of death. *Forensic Sci Int* 2012;220: 232-8.

30. Levy AD, Harcke HT, Getz JM, Mallak CT, Caruso JL, Pearse L, Frazier AA, et al. Virtual autopsy: two- and three-dimensional multidetector CT findings in drowning with autopsy comparison. *Radiology* 2007; 243:862-8.

31. Oyake Y, Aoki T, Shiotani S, Kohno M, Ohashi N, Akutsu H, et al. Postmortem computed tomography for detecting causes of sudden death in infants and children: retrospective review of cases. *Radiat Med* 2006; 24 :493-502.

32. Sakurai T, Michiue T, Ishikawa T, Yoshida C, Sakoda S, Kano T, Oritani S, Maeda H. Postmortem CT investigation of skeletal and dental maturation of the fetuses and newborn infants: serial case study. *Forensic Sci Med Pathol* 2012; 8:351-7

33. Persson A, Jackowski C, Engström E, Zachrisson H. Advances of dual source, dualenergy imaging in postmortem CT. *Eur J Radiol* 2008;68(3): 446-55.

34. Ruttly G N. Are autopsies necessary? *Rechtsmedizin* 2007; 17(1): 21-8.

35. O'Donnell C, Woodford N. Post-mortem radiology—a new sub-speciality?. *Clin Radiol* 2008;63(11): 1189-94

36. Westphal S E, Apitzsch J, Penzkofer T, Mahnken A H, Knüchel R. Virtual CT autopsy in clinical pathology: feasibility in clinical autopsies *Virchows Arch* 2012;461(2): 211-19

37. Wichmann D, Obbelode F, Vogel H, Hoepker WW, Nierhaus A, Braune S, et al. Virtual Autopsy as an Alternative to Traditional Medical Autopsy in the Intensive Care Unit A Prospective Cohort Study. *An Int Med* 2012;156(2): 123-30.

38. Christe A, Flach P, Ross S, Spendlove D, Bolliger S, Vock P, et al. Clinical radiology and postmortem imaging Virtopsy; are not the same: specific and unspecific postmortem signs. *Leg Med* 2010; 12(5): 215-22.

39. Dirnhofer R, Jackowski C, Vock P, Potter K, Thali MJ. Virtopsy: minimally invasive, imagingguided virtual autopsy. *Radiographics* 2006;26(5): 1305-33.

41. O'Donoghue K, O'Regan KN, Sheridan CP, O'Connor OJ, Benson J, McWilliams S, et al. Investigation of the role of computed tomography as an adjunct to autopsy in the evaluation of stillbirth. *Eur J Radiol* 2012;81(7):1667-75.

42. Stawicki S P, Gracias V H, Schrag S P, Martin N D, Dean A J, Hoey B A. The dead continue to teach the living: examining the role of computed tomography and magnetic resonance imaging in the setting of postmortem examinations. *J Surg Edu* 2008;65(3): 200-5.

43. [http:// www.forim-x.com](http://www.forim-x.com) visit on 2014/04/30

Ladan soltanzadeh is with Educational Deputy of Urmia University of Medical Sciences, Urmia, Iran, Msc In Biomedical Eng, Amirkabir University of Technology, Iran.
Email: Ladan.soltanzadeh@gmail.com

Mehrdad Imanzadeh is with Biomedical Engineering Faculty, Amirkabir University of Technology, Tehran, Iran.

Hamid Keshvari is Corresponding Author and is Assistant professor of Department of Biomedical Engineering, Amirkabir University of Technology, 424 Hafez Ave, Tehran, Iran, 15875-4413, Tel: (+98) 21 64 54 24 81. ari@aut.ac.ir
Email: Keshv