

# An Improved MRI Segmentation for Atrophy Assessment

Rowayda A. Sadek\*

Computer Engineering Department, Arab Academy of Science and Technology  
Cairo, Egypt

Computer Engineering Department, College of Engineering and Technology, Arab Academy for Science  
Technology & Maritime Transport( AASTMT), Cairo, Egypt

## Abstract

An efficient brain segmentation technique of magnetic resonance image (MRI) is proposed for the sake of atrophy detection. Early detection of brain atrophy indicates many neurodiseases. The paper also proposes a new simple assessment for brain atrophy as an atrophy ratio measure. Experiments on cognitive normal and atrophied MRI Brain images demonstrate the promising segmentation results of the proposed method that yields more accurate segmentation results than the existing segmentation methods as well as a good early detection and assessment for brain atrophy.

**Keywords:** MRI – Brain - Atrophy - Segmentation.

## 1. Introduction

The advances in medical imaging over the last two decades have a compact effect on diagnosis, treatment planning and evaluation. Medical images almost are stored and represented digitally. Commonly used medical imaging types are ultrasound images; X-ray computed tomography, digital mammography, magnetic resonance image (MRI), etc. [1]. There are groups of non-invasive (i.e., no surgery is required) tests that provide information about the shape, size, and health of organ (e.g., brain) structures, as well as how well the organ functions during activities. MRI imaging is popular to obtain image of brain with high contrast, so it is important in detecting abnormal changes in different parts of brain in early stage. MRI scan is commonly used to look for brain tumors, blood clots, strokes, or other abnormalities that might account for Alzheimer's-like symptoms. MRI may show a decrease or shrinkage in the size of different areas of the brain which is called atrophy. Brain atrophy is the wasting away of vital brain tissue, either in response to a disease process or stress. More specifically, disease or stress destroys the white matter of the brain, thereby atrophying the tissue [2,3,4].

Medical images mostly contain unknown noise, inhomogeneity and complicated structure. Therefore, segmentation of medical images is an open task for

research. Medical image segmentation has been an active research area for a long time. There are many segmentation algorithms but there is no generic algorithm for totally successful segmentation of medical images [2,3]. The brain images segmentation is a complicated and challenging task. However, accurate segmentation of these images is very important for detecting tumors, edema, and atrophy [1,2,4]. The main objective of this paper is to develop and test an automatic recognition system for the atrophy happening in the brain by using enhanced segmentation technique to find specific anatomical structures in the MRI of the brain. Modified Segmentation is carried out in brain MRI images using the watershed transform algorithm with additional preprocessing due to its well defined properties and its computational efficiency [5,6]. The proposed approach provides the required preprocessing and co processing to overcome the well-known over-segmentation problem in watershed transform segmentation as well as the deblurring happened during MRI acquisition. An atrophy factor is proposed as an indicator for the percentage of atrophy (reduction) of the atrophied brain. The paper is organized as follows; section 2 demonstrates the co-processing techniques that are used in MRI to overcome the problems of noise and movements during acquisition. Section three reviews the medical image watershed based segmentation techniques. Section four describes the proposed technique procedure. Section five illustrates the simulation results and discusses them and finally section six reveals conclusion and future of the work.

## 2. MRI Brain Image Deblurring

The patient's movements during acquisition are the most common cause of MRI image blur and noise artifacts. Random movements produce a blurry and noisy image, mainly in the phase-encode direction and periodic motion which creates ghost images in the phase-encode direction [3]. MRI is usually suffering from blurring and inhomogeneity due to acquisition and moving causes. The

\* On temporary leave from FCI, Helwan University, Cairo, Egypt

field of image deblurring is concerned with the reconstruction or estimation of the uncorrupted image from a distorted and noisy one. There are various techniques used in image deblurring, such as the Lucy-Richardson method, the Van Cittert's iteration etc. To address image deblurring, some researchers have modified the image capture process or used multiple images to aid in deblurring [7]. Non-blind image deconvolution is the process of recovering a sharp image from an input image corrupted by blurring and noise, where the blurring is due to convolution with a known kernel and the noise level is known [8]. Most deblurring approaches rely on deconvolution techniques such as the Lucy-Richardson algorithm, Wiener filtering, and least-squares deconvolution [8,9].

### 3. Medical Image Watershed Based Segmentation

Medical images mostly contain unknown noise, in-homogeneity and complicated structure. Therefore, segmentation of medical images is a challenging and complex task. There is no universal algorithm for image segmentation, which would suit all kinds of images. Most of the segmentation algorithms just consider intensity of image and in noisy images; intensity is not trustful [3]. Therefore, this algorithm has not good result in low contrast, in-homogeneity and noisy images. Region segmentation may be used for finding homogeneous regions or complete object segmentation for identifying objects, which are semantically meaningful. Detecting lesions in brain images is usually driven by such low level image processing operations as smoothing and segmentation [2,3]. Image segmentation used the morphological watershed approaches, gives good results [5,6]. Therefore, brain watershed based segmentation but with additional precautions. After segmentation, features of resulting segments may be extracted and subsequently classify the segments according to their features such as white, gray, and fluids anatomically regions in brain. The successful usage of watersheds in image segmentation relies mostly on a good estimation of image gradients. However, background noise tends to produce spurious gradients, causing over-segmentation and degrading the result of the watershed transform. Also, low-contrast edges generate small magnitude gradients, causing distinct regions to be erroneously merged. Simply each local minimum becomes a seed of a new region; however this minimum is not necessarily a point inside a candidate region. Therefore a preprocessing procedure is a vital part in the watershed based segmentation.

#### 3.1 Watershed based Segmentation

Watershed transformation is a morphological based tool for image segmentation. [5,6]. The watershed transform can be classified as a region-based segmentation approach. The idea of watershed can be viewed as a landscape immersed in a lake; catchments basins will be filled up with water starting at each local minimum. Dams must be built where the water coming from different catchments basins may be meeting in order to avoid the merging of catchments basins. The watershed lines are defined by the catchments basins divided by the dam at the highest level where the water can reach in the landscape. As a result, watershed lines can separate individual catchments basins in the landscape [5,6]. The aim of the watershed algorithm is to search for the region of high intensity gradient (watersheds) that divides neighbored local minima (basin). Figure 1 shows an example with four minima associated to three basins. The watershed is located as shown to avoid that the water coming from adjacent basins join. An efficient watershed algorithm is proposed by Vincent et. al. [10]. Watershed is carried out efficiently by using a marker image [11]. A marker image defines included zero marker values of watershed line pixels. A marker image needs to be accurately calculated.

There are two types of markers, i.e. internal and external markers. Internal markers are imposed inside the objects to be identified; external markers are imposed outside the objects. Markers can be computed by various methods such as linear filtering, nonlinear filtering, or morphological processing. The choice usually is determined by the nature of the processed image. Brain based markers needs to be specified by both internal and external markers.

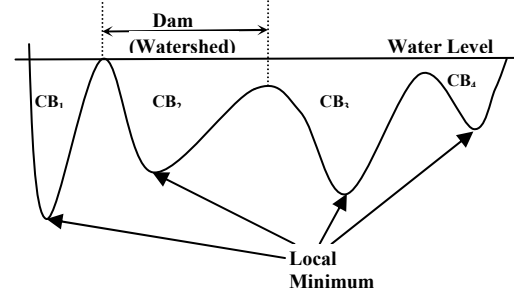


Fig. 1 Immersion process of watershed transforms. (CB is for catchments basins)

#### 3.2 Segmentation Pre-processing

Raw watershed algorithms are extremely vulnerable to noise. Watershed should present correct contours and may show other erroneous contours due to noise, therefore it may produce an oversegmentation of the image. Simply detected each local minimum becomes a seed of a new region, but this minimum is not necessarily a point inside a

candidate region. Preprocessing was carried out by using different techniques such as smoothing filters, simple morphology operations and markers [11,12]. The choice of preprocessing depends on the image nature. The aim of preprocessing is to get rid of irrelevant local minima by smoothing the interior of the objects which prevents splitting them by watershed lines to preserve the right borders of the segments.

Markers are artificially generated starting points for the watershed procedure. In fact they are seed points of the catchments. That guarantees that during the immersion process each marker point will grow to one region. Actually marker points are implemented as points of the zero value (deepest), and that makes them be starting points. The marker points can be obtained manually or by another segmentation algorithm (e.g. thresholding).

#### 4. Proposed Detection and Assessment Approach

The proposed technique deals with segmentation of the different types of tissues in the brain in order to detect the brain atrophy. It discriminates the grey-matter (GM), white-matter (WM) against cerebrospinal fluid (CSF) in the MRI. Preprocessing stage is required to image intensity non-uniformity noise, in-homogeneity correction. Preprocessed watershed segmentation technique is proposed to be used. Many watershed morphology algorithms are proposed for medical and remote sensing images [5,6]. MRI usually suffers from blurring effect due to acquisition and movement effects. Many techniques were used to restore images from blurring effects [8,9]. The proposed approach offers multi-layers of preprocessing for MRI image restoration as well as overcome the oversegmentation problem.

The proposed approach is carried out in three steps; multi-layers preprocessing, enhanced watershed segmentation and finally atrophy estimation. Atrophy based calculation (AT) determines the reduction (shrinkage) happened in the brain in all regions. AT considers grey-matter (GM), white-matter (WM) compared to cerebrospinal fluid (CSF) in an MRI image. AT can indicate many diseases such as multiple sclerosis, Alzheimer's disease, Pick's disease, senile dementia, vascular dementia, stroke, etc. The approach details are as follows;

##### 4.1 MRI Preprocessing

Real edges with high strength of intensity is one of the most important factors that affecting accuracy of segmentation results. One layer restores the image by treating the blurring effect of MRI acquisition. The other layer removes the noise that may affect segmentation results. This step reduces the erroneously segmented

regions that have small size and don't satisfy the problem criteria. Deblurring MRI is carried out by using Lucy-Richardson method to reduce the blurring effect of MRI acquisition [8,9]. The noise sensitivity of Lucy-Richardson is handled by using median filter. Median filtering is carried out to eliminate noise that may be represented erroneously as small local minima. Figure (2) shows the MRI original captured image for cognitive normal person, its deblurred version and the smoothed version. Subjectively, the deblurring effect is clear as well as strengthening of the true edges which are needed in the segmentation step.

##### 4.2 Marker-Controlled Watershed Segmentation

This step finds the segmented image by using marker controlled based segmentation algorithm. Watershed is carried out by using marker imposed image. The marker image defines the real clustered white and gray matter regions in the MRI of the brain.

The algorithm separates clustered white matters and gray matters apart from CSF in MRI brain image using shape markers and marking function in a watershed-like algorithm. A shape marker extraction scheme used is based on calculating dual marking; internal (nucleus) and external (outer) markers for more accurate segmentation of clustered regions.

The procedure of the watershed by using efficient markers is as follows; (1) Internal markers are extracted by computing the extended minima transform. (2) External markers are obtained by distance transform. (3) Regulating the minima markers by using morphology mask at the internal markers. (4) Watershed the imposed image with its markers.

Calculate Internal Markers by locating regional minima locations. Regional minima are defined as connected components of pixels with the same intensity value, and the pixels of the external boundaries all have higher intensity value. Internal markers extraction scheme uses Extended-minima transform, which is the regional minima of the H-minima transform in extracting inner shape. H-minima transform obtains good segmentation results from distance map. In order to estimate the optimal h-value, a size-invariant segmentation distortion evaluation function is defined based on the fitting residuals between the segmented region boundaries and fitted models [13].

External marker contours which use outer distance transform as an outer marking function, can be calculated by identified the background in the gradient image, i.e. to find pixels midway between the internal markers. The segmented region boundary is calculated by using Euclidean distance transform [14]. Then compute watershed of the resultant segmented image. The resulting ridge lines are the external marker. Regulate the minima

marker by using morphological mask of internal markers. Internal marker is based on the H -minima transform is introduced to obtain good segmentation result [13]. External Markers which estimate the segmented region boundaries are calculated by using watershed algorithm. With the aid of Euclidian distance transform [14]. Then the gradient image is modified with the minima imposition procedure using both internal and external markers. In gradient image, minima exist only in marked locations; other pixels intensity has been increased to suppress other regional minima. Finally, calculation the watershed for the image with its imposed markers has carried out.

### 4.3 Atrophy Assessment

For the early detection of the atrophy (in first MRI radiology check up visit), use the white and gray matter region as a ratio of the whole brain. This ratio may give a clue for the radiology about atrophy degree. In case there is a highly shrinkage this ratio will be small compared to a normal cognitive brain corresponding ratio. Atrophy ratio (AT) can be estimated by considering the gray (GM) and white matters (WM) regions compared to the whole brain size including WM, GM, and cerebrospinal fluid (CSF) [1,4]. AT can indicate many diseases such as multiple sclerosis, Alzheimer's disease, Pick's disease, senile dementia, vascular dementia, stroke, etc. Atrophy based calculation; AT is calculated for an MRI image as follows;

$$AT = \frac{GM + WM}{GM + WM + CSF} \quad (1)$$

Where, GM, WM and CSF indicate the region area of gray matter, white matter and fluid respectively. If AT is small this indicates high atrophy in the brain. A threshold experimentally extracted when a large database is available. The threshold to compare with should be selected based on the patient age, patient gender or from previous MRI visit. Assume having a follow up MRI visit. Since the patient has previous MRI, a progressively diagnosis can be done from previous and recent MRIs. Atrophy Factor (AF) is introduced to detect the atrophy rate from previous to recent MRI images for the same patient with a specific time interval. AF calculates the reduction happened in brain tissues normalized with the previous case. The atrophy factor (AF) can be calculated as follows;

$$AF = \frac{AT_1 - AT_2}{AT_1} \quad (2)$$

Where  $AT_1$  and  $AT_2$  indicate the atrophy of whole brain in two consecutive follow up MRI visits with a specific time difference (one year). For AF is too small near to zero, this means that no atrophy happened during this period and as the factor increases, it indicates high atrophy.

## 5. Simulation And Discussion

The standard mode of 3D medical image acquisition obtains many 2D slices, therefore particular 2D slices are used in the experiment to examine the proposed approach. The algorithm was run on sample images of the database "The Whole Brain Atlas" [15]. The MRI imaging protocol included sagittal T1-weighted images, axial images and oblique coronal T2-weighted images. In this paper, a set of cross-sectional 2D slices from atlas database is used. The simulation is carried out for many samples of cognitive normal (CN) and atrophied versions.

The simulation is carried out to examine the proposed approach of the tailor made watershed algorithm for sake of the atrophy analysis. A coronal T2-weight image for a cognitive normal person is used in figure (2) to show the effect of the proposed deblur and denoise preprocessing technique. The deblurring restores the edges of the image and the denoising remove the noise and undesirable effect of deblurring algorithm to avoid oversegmentation. The marker image is obtained for the original image and the preprocessed one. Figure (3) shows the calculated markers located on the image. Figure (3) demonstrates the effect of the preprocessing step in determining the markers. The change in marker is subjectively clear either by canceling some erroneous markers or by merging others. External markers based on the distance transform are calculated before and after preprocessing. Figure (4) shows the imposed markers on the image and their watershed. Obviously the erroneous regions resulted without using preprocessing compared to those by using preprocessing. Figure (5) demonstrates the segmentation of the marked image by using the Otsu's method with traditional mathematical morphology (opening and closing) as postprocessing compared to proposed one. Otsu's method searches for the threshold that minimizes the intra-class variance which is defined as the weighted sum of variances of the two classes [16]. The chosen threshold for Otsu's minimizes the intraclass variance of the black and white pixels. The resultant segmented black and white image as well as the other segmented image using the proposed method are used in the atrophy estimation by using the atrophy estimation from Eq.1. Table I illustrates the results.

Consider atrophied brain of the same patient was captured in a follow up visit. Figure (6) shows the original MRI of atrophied brain, watershed segmentation, the segmentation using proposed approach and the traditional segmentation. Since two different MRI are available for the same patient with time difference one year, atrophy factor (AF) given in Eq.2 can be calculated. The atrophy ratio AT and are calculated for normal brain and atrophied one for the same patient without and with preprocessing. AT and AF values are illustrated in the table I. From table I, AF without

considering preprocessing is 6.81% which means reduction happened with this percentage. In case of considering the preprocessing AF is 11.05%. This may give an early clue about atrophy detection. For traditional methods, AF 20.29% which is indicates false result that may not be counted on. Simulation proved that the proposed technique gives promising results compared to the traditional techniques in calculating atrophy ratio.

## 6. Conclusion

MRI scan is an important tool in the diagnosis of the different diseases in brain. The proposed method is capable of segmenting brain lesions in the 2D brain image dataset. The high accuracy achieved results offer easy reliable detection of the brain atrophy for brain attacked by neurodegenerative disease, even before cognitive symptoms interfere with daily function. Further improvement of the algorithm will focus on extending it to 3D brain imaging, to calculate accurate volumetric of the background and lesion. Other future work is in the classification of the specific regions of interest for differential diagnosis of different neurodegenerative disease. Also, using different modalities and have inter-modality estimation for atrophy. Have a thoroughly experimental testing to large number of cases can give a clue about the threshold that can be used as a judgment boundary indicator for atrophy.

## 7. References

- [1] McEvoy et al., "Alzheimer Disease: Quantitative Structural Neuroimaging for Detection and Prediction of Clinical and Structural Changes in Mild Cognitive Impairment". Radiology, 2009
- [2] Atkins M. S., Mackiewicz B. T., "Fully Automatic Segmentation of the Brain in MRI," IEEE Trans. on Medical Imaging, vol. 17, no. 1, February 1998.
- [3] Clarke L. P., Heine, et al., "MRI Segmentation: Methods and Applications, Elsevier Publishers," Magnetic Resonance Imaging, vol. 13, no. 3, 1995.
- [4] J. Sastre-Garriga et. al., "Grey and White Matter Volume Changes in Early Primary Progressive Multiple Sclerosis: a Longitudinal Study" Brain (2005), 128, 1454–1460
- [5] L. Najman and M Schmitt, "Geodesic saliency of watershed contours and hierarchical segmentation," IEEE Trans. on Pattern Analysis and Machine Intelligence, Vol. 18, Issue 12, 1996, pp. 1163-1173
- [6] P. Moreels and S.E. Smrekar, " Watershed Identification of Polygonal Patterns in Noisy SAR Images", IEEE Trans. On Image Processing, Vol. 12, No. 7, July 2003
- [7] L. Yuan, J. Sun, L. Quan, and H.-Y. Shum. Image deblurring with blurred/noisy image pairs. ACM Trans. on Graphics, 26(3):1:1–1:10, July 2007.

- [8] Biggs, D.S.C. "Acceleration of Iterative Image Restoration Algorithms." Applied Optics. Vol.36. No.8, 1997, pp.1766–1775.
- [9] L.Yuan, J.Sun, L.Quan, and H.-Y. Shum." Progressive interscale and intra-scale non-blind image deconvolution".ACM Transactions on Graphics, 27(3):74:1–74:10, Aug. 2008.
- [10] L. Vincent and P. Soille "Watershed in Digital Space: An Efficient Algorithm Based on Immersion Simulations," IEEE Transactions on Pattern Analysis and Machine Intelligence, vol.13, no. 6, pp. 583-593, 1991.
- [11] S. Beucher, F. Meyer, Morphological segmentation. Journal of Visual Communication and Image Representation, Vol. 1, Oct. 1990
- [12] M. Vardavoulia, I. Andreadis, PH. Tsalides, A New Vector Median Filter for Colour Image Processing, Pattern Recognition Letters 22, pp. 675–689, 2001.
- [13] Soille, P., Morphological Image Analysis: Principles and Applications, Springer-Verlag, 1999, pp. 170-171.
- [14] B. Heinz, J Gil, D. Kirkpatrick, and M.Werman, "Linear Time Euclidean Distance Transform Algorithms," IEEE Trans,on Pattern Analysis and Machine Intelligence, Vol. 17, No. 5, May 1995, pp. 529-533.
- [15] K. A. Johnson and J. A. Becker, The Whole Brain Atlas. <http://www.med.harvard.edu/AANLIB>
- [16] Y. Zhang and L. Wu, "Fast Document Image Binarization Based on an Improved Adaptive Otsu's Method and Destination Word Accumulation", Journal of Computational Information Systems (2011) 1886-1892

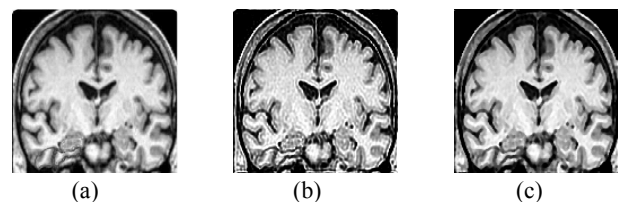


Fig. 2 MRI Preprocessing (a) Original (b) Deblurred image (c) Smoothed image

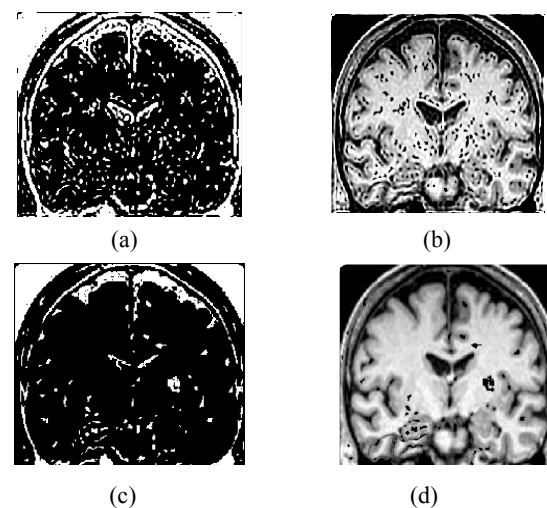


Fig. 3 Internal markers without (a,b)/ with (c,d) preprocessing: (a,c) Extended minima (b,d) Located Extended minima

Table I: Atrophy Measures

<i>Factors</i>	<i>Marker based Watershed</i>	<i>Proposed Approach</i>	<i>Traditional</i>
$AT_{CN}$	0.8497	0.7430	0.6156
$AT_{Atrophied}$	0.7918	0.6609	0.4907
AF%	6.81	11.05	20.2889

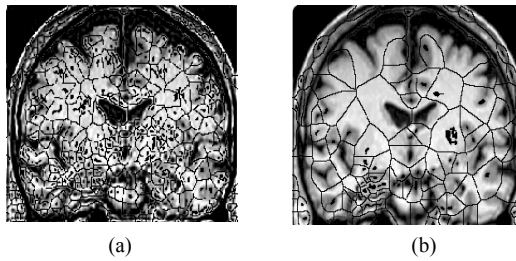


Fig. 4 Imposed image with its markers (a) without preprocessing: (b) with preprocessing




Fig. 5 Segmented image

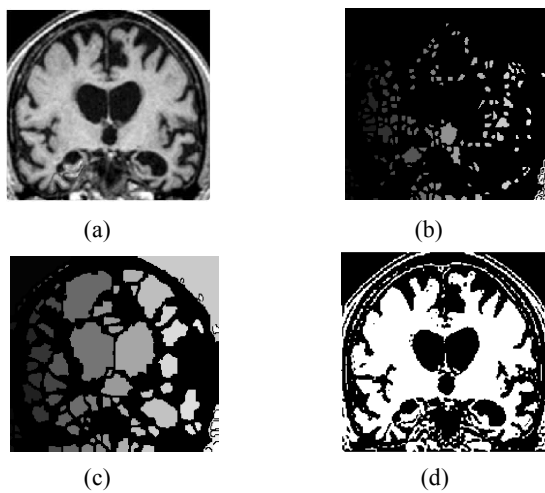


Fig. 6 Atrophied Brain MRI: (a) Original (b) watershed segmented (c) segmented with the proposed approach (d) segmented with the traditional method